HYALURONIC ACID SODIUM SALT, 0.2% SPRAY AND ITS USE ON INFLAMMATORY SKIN CONDITIONS OF THE LOWER EXTREMITY

Brett C Chatman, BA* • Ashley N Mastrangelo, BA, MS* • Tracey Vlahovic, DPM**

Temple University School of Podiatric Medicine - Philadelphia, PA • *Fourth year student • **Associate Professor

INTRODUCTION

Past research has reported on the impact of topical Low Molecular Weight Hyaluronic Acid (Bionect, Innocutis) applied after cosmetic procedures and on various inflammatory skin conditions.[1,2] HA is a biological polysaccharide (glucosaminoglycan) that is a major component of the extracellular matrix of connective tissues that partially blocks the COX-2 inflammation pathway and therefore allows for a steroid free regimen for inflamed skin.[3,4] It is also thought that HA stimulates cell proliferation and maximizes skin hydration; which makes it an ideal candidate for both peri-wound skin concerns and superficial ulcer.[5]

MATERIALS & METHODS

This is an open-label single arm study on patients with stasis dermatitis on the lower leg. Subject involvement and characteristics include six female and male patients (age 31-78) who have been previously diagnosed with stasis dermatitis on the lower leg.

Upon initial visit, patients were assessed by means of examination by student doctor and senior podiatrist detailing level of pruritis, patient satisfaction and change of pigmentation. Level of pruritis assessed on a four point scale: level 1, no level of pruritis; level 2, minimal pruritis; level 3, moderate pruritis; and level 4, severe pruritis. Degree of satisfaction assessed on a four point scale: level 1, no satisfaction; level 2, minimal satisfaction; level 3, moderate satisfaction; level 4, completely satisfied. Changes of pigmentation determined by size of wound bed upon initial visit and first visit post-Low Molecular Weight Hyaluronic Acid (LMW-HA) spray use.

Patients were advised to clean and disinfect skin prior to treatment and apply a thin layer of a preparation containing LMW-HA spray without extensive rubbing onto the wound surface two times per day. Wound surface should be covered with a sterile gauze pad after application.

CASE STUDIES

PATIENT 1

78 year old female

Medical History:
Type II diabetes

Description of Skin:
Erythematous/purple plaques, macerated and scaling rash bilaterally in a moccasin distribution with xerosis noted on the plantar aspect of the foot with scaling.

Diagnosis per Biopsy:
Spongiform dermatitis

Previous Treatments:

1. Ciclopirox qd and Keflex 250mg qid.
2. Triamcinolone 0.1% cream bid, Econazole Cream, Urea cream 40%, applied twice daily.

Treatment Plan Modified to:
LMW-HA bid to affected areas and prescription based moisturizer qd.

PATIENT 2

56 year old female

Medical History:
Type II diabetes, hypertension, former smoker

Description of Skin:
Nodular, papular, dry, pruritic rash located on the dorsum of the foot bilaterally foot causing immense discomfort.

Diagnosis per Biopsy:
Lichen nitidus

Previous Treatments:

1. Hydrocortisone 1%.
2. Triamcinolone acetonide 0.1% cream bid.

Treatment Plan Modified to:
LMW-HA bid to affected.

PATIENT 3

62 year old female

Medical History:
Borderline diabetic, hypertension, hypercholesterolemia, former smoker.

Description of Skin:
Well-circumscribed, erythematous base with silver, dry, scaling and peeling skin located on plantar heels and balls of the feet bilaterally.

Diagnosis per Biopsy:
Psoriasis

Previous Treatments:

1. Over the counter moisturizer.
2. Urea 40% bid, Triacinolone acetonide 0.1% cream bid.

Treatment Plan Modified to:
LMW-HA bid to affected, prescription strength moisturizere qd and Calcipotriene 0.005% topical cream bid.

PATIENT 4

64 year old female

Medical History:
Type I diabetes, asthma.

Description of Skin:
Pruritic, ulcerative lesion on the left medial lower leg with surrounding erythema and fibrogranular base.

Diagnosis per Biopsy:
Contact dermatitis

Previous Treatments:

1. Clindamycin 300mg PO tid, Avelox 400mg PO, Bactroban topical bid.

Treatment Plan Modified to:
LMW-HA bid to affected, Microcyn spray prn to pruritic areas.

PATIENT 5

49 year old female

Medical History:
Venous insufficiency (deep vein thrombosis), hypertension, chronic tinea pedis, current smoker.

Description of Skin:
Xerosis bilaterally with hyperpigmentation and cellulitis of left foot; scaling to digits 2-4 on left foot.

Diagnosis per Biopsy:
Venous stasis dermatitis

Previous Treatments:

1. Medrol dose pack, Ketoconazole.

Treatment Plan Modified to:
LMW-HA bid to affected, prescription strength moisturizer qd.

PATIENT 6

31 year old female

Medical History:
Hypercholesterolemia, tinea pedis.

Description of Skin:
Pruritic, erythematous lesion on the dorsum of the left foot.

Diagnosis per Biopsy:
Venous stasis dermatitis

Previous Treatments:

1. Desoximetasone.

Treatment Plan Modified to:
LMW-HA bid to affected, prescription strength moisturizer bid.

RESULTS

PRURITIS

Level of pruritis for all patients upon initial visit was severe. Upon re-examination the level for all patients significantly decreased to either zero or minimal (3.67±0.52 vs.1.5±0.5).

SATISFACTION

Level of satisfaction for all patients upon initial visit was grossly dissatisfied. Upon re-examination, patient satisfaction was greater for all patients (1±0 vs. 3.67±0.52).

PIGMENTATION

Area of affected area upon initial visit was (4.6±4.06). Upon re-examination the length and width of affected area was smaller (0.93±1.0). See figures 1-4.

Figure 1: Patient #2, right foot, appointment before LMW-HA application.

Figure 2: Patient #2, right foot, appointment after LMW-HA application.

Figure 3: Patient #2, left foot, appointment before LMW-HA application.

Figure 4: Patient #2, left foot, appointment after LMW-HA application.

	Appointment before LMW-HA application	Appointment after LMW-HA application
Pruritis	3.67 ± 0.52	1.5 ± 0.5
Satisfaction	1 ± 0	3.67 ± 0.52
Hyperpigmentation (mm)*	4.6 ± 4.06	0.93 ± 1.0

Table 1: Pruritis, satisfaction and hyperpigmentation at visit prior to LMW-HA application and after LMW-HA application. Values are expressed as mean ± SD, where n=6.

*Hyperpigmentation represented by area (length x width) ± SD in mm.

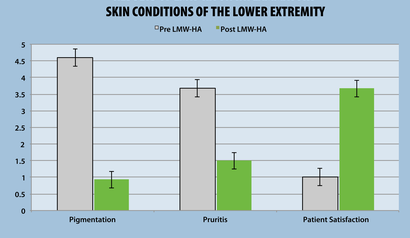

Figure 1

Figure 2

Figure 3

Figure 4

CONCLUSION

Due to the anti-inflammatory properties of LMW-HA and the quality of the skin at the medial aspect of the lower leg, there was a reduction in pigmentation, pruritis and increase in overall patient satisfaction in the use of a lower steroid-free regiment. The results of this study suggest that the abundance of LMW-HA in the dermis, epidermis and stratum corneum, along with its water-binding capacity, allow hydration of the skin in tissue inflammation, resulting in less pruritis and hyperpigmentation. Although further studies are required, this study suggests the multifactorial roles of LMW-HA in treatment of both peri-wound skin and superficial ulcers.

REFERENCES

1. Schrager, HM, Rheinwald, JG and Wessels, MR. (1996). Hyaluronic Acid Capsule And The Role of Streptococcal Entry Into Keratinocytes In Invasive Skin Infection. Journal of Clinical Investigation: November 1; 98(9): 1954-1958.

2. Weindi, G. Schaller, M, Schafer-Korting, M and Korting, HC. (2004). Hyaluronic Acid in the Treatment And Prevention Of Skin Diseases: Molecular Biological, Pharmaceutical And Clinical Aspects. Skin Pharmacology and Physiology: Sep-Oct; 17(5): 207-13.

3. Schlesinger, T and Powell, CR. (2012). Efficacy and Safety of a Low-Molecular Weight Hyaluronic Acid Topical Gel in the Treatment of Facial Seborrheic Dermatitis. The Journal of Clinical and Aesthetic Dermatology: October; 5(10): 20-23.

4. Gariboldi, S et al. (2008). Low Molecular Weight Hyaluronic Acid increases The Self-Defense of Skin Epithelium By in Induction of Beta-Defensin 2 via TLR2 and TLR4. Journal of Immunology: Aug 1; 181(30: 2103-10.

5. Gazzabin, L, Bucalossi, M, Mariani, F and Serantoni, S. (2011). Spray formulation of silver and hyaluronic acid in the treatment of superficial cutaneous ulcers of different etiopathogenesis: analysis of fifty-four clinical cases. Panminerva Medica: September; 53(3): 185-91.

Download a copy of this poster onto your mobile device at the QR code below:

Supported by:
Innocutis Holdings, LLC